ORIGINAL CONTRIBUTION

Autoimmune Epilepsy

Clinical Characteristics and Response to Immunotherapy

Scan for Author Audio Interview

Amy M. L. Quek, MBBS; Jeffrey W. Britton, MD; Andrew McKeon, MD; Elson So, MD; Vanda A. Lennon, MD, PhD; Cheolsu Shin, MD; Christopher J. Klein, MD; Robert E. Watson Jr, MD, PhD; Amy L. Kotsenas, MD; Terrence D. Lagerlund, MD; Gregory D. Cascino, MD; Gregory A. Worrell, MD, PhD; Elaine C. Wirrell, MD; Katherine C. Nickels, MD; Allen J. Aksamit, MD; Katherine H. Noe, MD; Sean J. Pittock, MD

Objective: To describe clinical characteristics and immunotherapy responses in patients with autoimmune epilepsy.

Design: Observational, retrospective case series.

Setting: Mayo Clinic Health System.

Patients: Thirty-two patients with an exclusive (n=11) or predominant (n=21) seizure presentation in whom an autoimmune etiology was suspected (on the basis of neural autoantibody [91%], inflammatory cerebrospinal fluid [31%], or magnetic resonance imaging suggesting inflammation [63%]) were studied. All had partial seizures: 81% had failed treatment with 2 or more antiepileptic drugs and had daily seizures and 38% had seizure semiologies that were multifocal or changed with time. Head magnetic resonance imaging was normal in 15 (47%) at onset. Electroencephalogram abnormalities included interictal epileptiform discharges in 20; electrographic seizures in 15; and focal slowing in 13. Neural autoantibodies included voltage-gated potassium channel complex in 56% (leucine-rich, glioma-inactivated 1 specific, 14; contactin-associated proteinlike 2 specific, 1); glutamic acid decarboxylase 65 in 22%; collapsin response-mediator protein 5 in 6%; and Ma2, *N*-methyl-D-aspartate receptor, and ganglionic acetylcholine receptor in 1 patient each.

Intervention: Immunotherapy with intravenous methylprednisolone; intravenous immune globulin; and combinations of intravenous methylprednisolone, intravenous immune globulin, plasmapheresis, or cyclophosphamide.

Main Outcome Measure: Seizure frequency.

Results: After a median interval of 17 months (range, 3-72 months), 22 of 27 (81%) reported improvement postimmunotherapy; 18 were seizure free. The median time from seizure onset to initiating immunotherapy was 4 months for responders and 22 months for nonresponders ($P<.05$). All voltage-gated potassium channel complex antibody–positive patients reported initial or lasting benefit ($P<.05$). One voltage-gated potassium channel complex antibody–positive patient was seizure free after thyroid cancer resection; another responded to antiepileptic drug change alone.

Conclusion: When clinical and serological clues suggest an autoimmune basis for medically intractable epilepsy, early-initiated immunotherapy may improve seizure outcome.

Arch Neurol. 2012;69(5):582-593. Published online March 26, 2012. doi:10.1001/archneurol.2011.2985

Author Affiliations: Departments of Laboratory Medicine and Pathology (Drs Quek, McKeon, Lennon, Klein, and Pittock), Neurology (Drs Britton, McKeon, So, Lennon, Shin, Klein, Lagerlund, Cascino, Worrell, Wirrell, Nickels, Aksamit, and Pittock), Immunology (Dr Lennon), and Radiology (Drs Watson and Kotsenas), Mayo Clinic, College of Medicine, Rochester, Minnesota; and Department of Neurology, Mayo Clinic, College of Medicine, Scottsdale, Arizona (Dr Noe).

ANTIEPILEPTIC DRUGS (AEDS) are the mainstay of treatment for epilepsy, but seizures continue in one-third of patients despite appropriate AED therapeutic trials.[1] Even in the current era, the etiology of epilepsy often remains unclear.[2] Seizures are a common symptom in autoimmune neurologic disorders, particularly in limbic encephalitis or multifocal paraneoplastic disorders.[3-16] Autoantibody specificities recognized in the setting of paraneoplastic limbic encephalitis include antineuronal nuclear antibody type 1, collapsin response-mediator protein 5 (CRMP-5), and Ma2. Voltage-gated potassium channel (VGKC) complex and glutamic acid decarboxylase 65 (GAD65) antibodies, often nonparaneoplastic in etiology, have been reported in patients with limbic encephalitis[7,13,15,16] and idiopathic epilepsy with AED-resistant seizures.[17-22] Newly identified autoantibody specificities that

For editorial comment see page 565

CME available online at www.jamaarchivescme.com and questions on page 564

©2012 American Medical Association. All rights reserved.
Downloaded From: http://archneur.jamanetwork.com/ on 05/25/2013

strongly correlate with clinical seizures include *N*-methyl-D-aspartate (NMDA),[23] γ-aminobutyric acid B,[24] and α-amino-3-hydroxy-5-methyl-4-isoxazolepropionic acid (AMPA) receptors.[25]

Accumulating data support an autoimmune basis in patients with AED-resistant seizures,[17-22] including those lacking a typical "limbic encephalitis" phenotype.[26-28] Identification of an immune basis is important because adjunctive immunotherapy may slow, halt, or even reverse the epileptogenic process in these patients. In a cohort study, autoimmune antibodies were detected in 14% of patients with epilepsy.[27] This study, along with several case reports and series,[17,19,22] suggested a potential benefit of immunotherapy in improving seizure control. Herein, we review the clinical characteristics and responses to immunotherapy for patients with suspected autoimmune epilepsy, evaluated jointly in an Autoimmune Neurology Clinic and Epilepsy Clinic, whose sole or predominant presenting symptom was recurrent, uncontrolled seizures.

METHODS

With approval of the Mayo Clinic institutional review board, we searched the Mayo Clinic computerized diagnostic index to identify patients who were evaluated in both the Autoimmune Neurology Clinic and Epilepsy Clinic between January 1, 2005, and December 31, 2010, whose evaluations led to a diagnosis of autoimmune epilepsy. Autoimmune epilepsy was defined as (1) epilepsy as the exclusive (n=11) or predominant (n=21) presenting concern and (2) autoimmune pathogenesis suspected by the treating physicians based on detection of a neural autoantibody, inflammatory cerebrospinal fluid (CSF) (leukocytosis or CSF-exclusive oligoclonal immunoglobulin bands), or magnetic resonance imaging (MRI) characteristics suggesting inflammation (T2 hyperintensities, contrast enhancement on gadolinium studies, and/or restricted diffusion).

Demographic and clinical characteristics (seizure semiology, clinical course, and associated symptoms) were recorded. Head MRIs and whole-body radiolabeled fluorodeoxyglucose positron emission tomography (FDG-PET) scans were reviewed by at least 2 investigators (A.M.L.Q., A.L.K., and R.E.W.) blinded to the clinical data (one, a neuroradiologist). The electroencephalogram (EEG) studies were scalp recordings acquired via electrodes applied using the international 10-20 system for electrode placement. All routine EEGs comprised two 1-channel and all prolonged 30-channel digital EEG recordings. Longitudinal and transverse bipolar, Cz and ear/mastoid referential, and Laplacian montages were used as indicated to optimize seizure detection and localization. Results of neural autoantibody screening were recorded.[3,13,14] A composite substrate of mouse cerebellum, midbrain, stomach, and kidney was used in a standardized indirect immunofluorescence assay to detect the following neuronal and glial nuclear and cytoplasmic IgG autoantibodies: ANNA types 1 (anti-Hu), 2 (anti-Ri), and 3; Purkinje cell cytoplasmic autoantibodies types 1 (anti-Yo), 2, and Tr; CRMP-5; amphiphysin; and antiglial/neuronal nuclear antibody type 1. In-house assays included radioimmunoprecipitation to detect antibodies reactive with cation channel complexes (neuronal voltage-gated calcium channels [P/Q type and N type], VGKC complex, nicotinic acetylcholine receptors of skeletal muscle and autonomic ganglionic types) and GAD65, enzyme-linked immunosorbent (skeletal muscle striational antibodies) and recombinant Western blot (CRMP-5–IgG). Frequencies of these neural autoantibodies in healthy controls (**Table 1**, footnote) were previously reported.[29] Ma/Ta antibodies were identified via recombinant Western blot (Athena Diagnostics).

Supplementary immunofluorescence assays were performed on sections of mouse cerebral cortex, hippocampus, and thalamus to detect synapse-reactive IgG autoantibodies specific for NMDA, AMPA, and γ-aminobutyric acid B receptors. *N*-methyl-D-aspartate receptor seropositivity was confirmed molecularly by immunofluorescence on HEK293 cells transfected with NMDA receptor complementary DNA (product of EUROIMMUN). Sera positive for VGKC complex antibodies by radioimmunoprecipitation were analyzed further for IgGs specific for leucine-rich, glioma-inactivated 1 (Lgi1) or contactin-associated proteinlike 2 (Caspr2) using HEK293 cells transfected with Lgi1 or Caspr2 complementary DNA (product of EUROIMMUN). These proteins coprecipitate with Kv1 VGKC complexes solubilized from mammalian brain membranes and ligated with iodine 125–labeled α-dendrotoxin.[8,9] All sera tested in 126 healthy controls were negative for VGKC complex, Lgi1, or Caspr2 autoantibodies.

Response to immunotherapy was categorized on the basis of physician and patient reports of seizure freedom, seizure improvement (reduction in seizure frequency and severity), or no change.

Data were expressed as median (range and interquartile range) for continuous variables and counts (percentages) for categorical variables. Differences between responders (seizure freedom or improvement) and nonresponders were compared using an unpaired *t* test, analysis of variance, and Wilcoxon rank sum tests for continuous measures and χ^2 and Fisher exact tests for categorical variables.

RESULTS

CLINICAL CHARACTERISTICS

Clinical, radiological, EEG, autoimmune serologic values, and immunotherapeutic outcomes for 32 patients are presented in Table 1 and **Table 2**. All presented with recurrent seizures. Fifty-nine percent were female. Median seizure onset age was 56.0 years (range, 5-79 years). Median history of seizure activity prior to Mayo Clinic presentation was 5 months (range, 3 weeks to 12 years). An autoimmune basis was suspected based on detection of a neural autoantibody (91%), inflammatory CSF (leukocytosis or CSF-exclusive oligoclonal immunoglobulin bands) (31%), or MRI characteristics suggesting inflammation (63%).

SEIZURE AND EEG CHARACTERISTICS

Partial seizures were the predominant clinical presentation: simple partial and/or auras, 27 of 32 (84%); complex partial, 26 of 32 (81%); and secondary generalized tonic-clonic, 17 of 32 (53%). Seizure semiologies were variable or changed over time in 12 patients (38%). Most patients (81%) had received 2 or more AEDs at presentation (median, 3 AEDs), yet seizures were frequent: 26 (81%) had daily seizures; the remaining had at least 1 seizure per month.

Two patients had undergone epilepsy surgery without seizure benefit elsewhere (anterior temporal lobectomy plus amygdalohippocampectomy and frontal corticectomy, patients 5 and 14, respectively); none had a neoplasm. Perivascular chronic inflammatory cell infiltrates (mainly T lymphocytes) were noted on histopathology review at

©2012 American Medical Association. All rights reserved.
Downloaded From: http://archneur.jamanetwork.com/ on 05/25/2013

Table 1. Clinical Characteristics[a]

Patient/ Sex/ Age, y	Epilepsy Duration, mo	Seizure Type/Semiology	Neurologic Association	No. of AEDs/ Seizure Frequency	EEG Abnormalities (Region)	MRI Probable Inflammatory Changes[b]	CSF Abnormality (Value)[c]	Autoantibody Profile (Titer)[d,e]	ITX (Frequency, No. of Treatments/ Duration)	Post-ITX Seizure Outcome and Antibody Titer
1/M/61	2.75	SPS: bilateral independent facial clonus; auras: flushing, diffuse tingling; CPS (variable semiologies): bicycling, oral automatisms, unilateral limb posturing[f]	Cognitive	2/Daily	IED (fronto-temporal)	L medial temporal (Gad+) (DWI+)	Normal	VGKC complex (2.58), Lgi1+, Caspr2–, TPO (12.2)	IVIg (daily, 3; weekly, 5); IVMP (daily, 5; weekly, 4); PLEX (7); MMF (4 mo, ongoing)	Seizure freedom (9 mo)
2/M/61	10	Auras: déjà vu; CPS: unresponsive staring		2/Monthly	Generalized slowing		Protein level (80)	VGKC complex (0.27), Lgi1–, Caspr2–	No ITX; thyroid cancer detected and resected; neurologic symptoms subsided after cancer treatment	Seizure freedom (after tumor removal, 22 mo)
3/F/16	1.5	Changed over time; SPS (variable semiologies): leg jerking, UE jerking; EPC: continuous low amplitude R finger ± facial jerking; CPS: unresponsive staring; rare GTC[f]	Cognitive; personality	3/Daily	IED (temporal), IA (multifocal, temporal and extratemporal), FS (temporal), generalized slowing	R temporal posterolateral cortex (Gad–) (DWI–)	OCB (4)	CRMP-5	IVMP (daily, 5); oral dexa (5 d monthly for 24 mo); repeated cycles of IVMP owing to relapses (×2); MMF (2.5 y, ongoing)	Seizure improvement; post-ITX CRMP-5–
4/M/54	2.5	SPS: frequent episodes of olfactory hallucinosis, head pressure, dysarthria, then fatigue[f]		3/Daily	Normal		Protein level (76)	CRMP-5	IVMP (daily, 5); MMF (26 mo)	Seizure freedom (15 mo); post-ITX CRMP-5–
5/M/64[g,h]	11.5	Changed over time; auras and CPS (variable): diffuse hot sensation, auditory hallucinosis; GTC[f]		3/Monthly	IED (temporal), FS (temporal), generalized slowing	Post–temporal lobectomy gliosis; R MTS	WBC count (7), protein level (68)	VGKC complex (1.2), Lgi1+, Caspr2–	IVMP (daily, 5); IVIg (daily, 3; weekly, 9; monthly, 10; every 2 mo, 3); MMF (4.5 y)	Seizure freedom (48 mo); post-ITX VGKC complex, 0.14
6/F/67[g]	5	GTC out of sleep (no reported SPS or CPS)		1/Monthly	IED (temporal), generalized slowing		Not done	VGKC complex (3.5), Lgi1–, Caspr2–	No ITX; seizures continued with first AED; subsequent change to second AED, with seizure freedom thereafter; eventually stopped taking all AEDs	
7/F/37	2.5	EPC occipital origin: unilateral visual hallucinosis, intermittent unilateral UE stiffness; CPS: intermittent confusion; GTC[f]	Cognitive	2/Monthly	IED (temporal and extratemporal), IA (extratemporal: EPC), FS (temporal)	R medial temporal, R thalamus, R occipital (Gad–) (DWI+), R MTS	WBC count (19), protein level (58)	None, TPO (49), RF	IVMP (daily, 5 × 2; monthly, 8); MMF (17 mo)	Seizure freedom (42 mo)
8/F/57[g,h]	5	Auras: unilateral visual hallucinosis and nausea; CPS: unresponsive staring, unilateral facial and UE posturing; GTC[f]	Cognitive	8/Daily	Generalized slowing		WBC count (7), protein level (61)	VGKC complex (4.21), Lgi1–, Caspr2–,TPO (61), RF	IVMP (daily, 5; fortnightly, 4; monthly, 2; every 2 mo, 2); MMF (3 y 4 mo)	Seizure freedom (48 mo); post-ITX VGKC complex, 0.39

(Continued)

©2012 American Medical Association. All rights reserved.
Downloaded From: http://archneur.jamanetwork.com/ on 05/25/2013

Table 1. Clinical Characteristics[a] (continued)

Patient/ Sex/ Age, y	Epilepsy Duration, mo	Seizure Type/Semiology	Neurologic Association	No. of AEDs/ Seizure Frequency	EEG Abnormalities (Region)	MRI Probable Inflammatory Changes[b]	CSF Abnormality (Value)[c]	Autoantibody Profile (Titer)[d,e]	ITX (Frequency, No. of Treatments/ Duration)	Post-ITX Seizure Outcome and Antibody Titer
9/F/35	4	SPS: intermittent unilateral LE paresthesia and posturing; GTC		3/Daily	Normal		Normal	GAD65 (3.38)	IVIg (daily, 4 × 2; twice weekly, 2)	Seizure freedom (18 mo); post-ITX GAD65, 2.06
10/F/48	12	Aura: olfactory and gustatory hallucinosis; CPS: unresponsive staring	Cognitive	4/Daily	IED (temporal), FS (temporal)	L medial temporal (Gad–) (DWI –)	Normal	GAD65 (48.6), TPO (>950)	Lost to follow-up	
11/F/79	3.75	EPC: unilateral UE and LE clonic jerking		0/Daily	IED (extratemporal), IA (extratemporal, EPC)	L frontal (Gad–) (DWI–)	Protein level (62), OCB (5)	None	IVMP (daily, 5; weekly, 3); CMP (monthly, 11)	No response
12/F/73[h]	7	Aura: rising abdominal sensation; CPS: unresponsive staring	Cognitive	3/Daily	FS (temporal), generalized slowing	R medial temporal (Gad–) (DWI–), R MTS	WBC count (7), protein level mildly elevated	VGKC complex (0.13), Lgi1+, Caspr2–, TPO (85)	IVMP (daily, 3; weekly, 2; fortnightly, 6; every 3 wk, 3; monthly, 2); Pred (4 mo)	Seizure freedom (15 mo); post-ITX VGKC complex, 0.24
13/F/39	36	Changed over time; auras: multiple daily episodes of "wave" down R side with unilateral piloerection, olfactory hallucinosis in past; SPS: unilateral L UE and LE jerking and pulling ± L facial; CPS: unresponsive staring; GTC	Cognitive	6/Daily	Normal	R medial temporal (Gad–) (DWI–), R MTS	Normal	VGKC complex (0.62), Lgi1+, Caspr2–, ANA, ENA	IVMP (daily, 3; weekly, 12; fortnightly, 3; every 3 wk, 2; weekly ongoing and tapering); MMF (3 mo, ongoing); rituximab for relapses of wavelike spells (1000 mg ×2)	Seizure improvement; post-ITX VGKC complex, 0.00
14/F/24	96	Auras: jamais vu, fear; CPS: unresponsive staring with oral and limb automatisms; GTC[f]	Cognitive; personality	7/Monthly	IED (temporal and extratemporal), FS (extratemporal), generalized slowing	Post–L frontotemporal corticectomy changes, bilateral MTS	Protein level (43)	GAD65 (698), TPO (165.5), ENA	IVMP (daily, 5) (developed avascular necrosis of hip; relapsed postoperatively); IVIg (daily, 3; fortnightly, 6; every 3 wk, 2); (daily, 3; fortnightly, 4; daily, 5; every 3 wk, 2); MMF (2 y, ongoing)	Seizure freedom (6 mo)
15/F/65	22	SPS (variable): unilateral UE jerking, unilateral and bilateral "jolt" sensation; auras: migrating paresthesias on scalp; CPS: unresponsive staring; GTC		3/Daily	FS (temporal)	L medial temporal (Gad–), bilateral MTS	Normal	VGKC complex (0.27), Lgi1+, Caspr2–, TPO (9)	IVMP (daily, 3; weekly, 8); MMF (1 mo, ongoing)	Seizure freedom (3 mo)

(Continued)

our institution in patient 5; details for the other patient are unavailable. Continuation of poorly controlled seizures prompted postoperative referral to Mayo Clinic.

All 32 patients had EEGs recorded in our institution (eTable 1, http://www.archneurol.com), with a median of 2 per patient (range, 1-14). Prolonged video EEG monitoring was performed in 13 (41%). The following abnormalities were recorded: interictal epileptiform discharges, 20; electrographic seizures, 15; focal slowing, 13; and generalized slowing, 12. Three patients (patients 4, 9, and 13) had no EEG abnormalities detected, of whom only 1 (patient 13) had MRI inflammatory changes.

©2012 American Medical Association. All rights reserved.
Downloaded From: http://archneur.jamanetwork.com/ on 05/25/2013

Table 1. Clinical Characteristics[a] (continued)

Patient/ Sex/ Age, y	Epilepsy Duration, mo	Seizure Type/Semiology	Neurologic Association	No. of AEDs/ Seizure Frequency	EEG Abnormalities (Region)	MRI Probable Inflammatory Changes[b]	CSF Abnormality (Value)[c]	Autoantibody Profile (Titer)[d,e]	ITX (Frequency, No. of Treatments/ Duration)	Post-ITX Seizure Outcome and Antibody Titer
16/M/54	3.25	Auras (variable): tingling traveling down body and limbs, darkening of vision; CPS: episodic confusion; GTC[f]	Cognitive; personality	1/Daily	IED (extra-tempo-ral), IA (extra-tempo-ral)	L medial temporal (Gad–) (DWI+), L caudate and putamen (Gad–) (DWI–), L MTS	Protein level (94)	VGKC complex (0.33), Lgi1+, Caspr2–	IVMP (daily, 5; weekly, 6; fortnightly, 6; every 3 wk, 2; fortnightly, 8; every 3 wk, 4; monthly, 6); (daily, 5; weekly, 6; fortnightly, ongoing for 6); MMF (1.5 y); AZA (started, ongoing)	Seizure freedom (3 mo); post-ITX VGKC complex, 0.00
17/F/60	3	Auras: epigastric rising followed by limb paresthesias, piloerection, multiple per day		3/Daily	IED (tempo-ral), IA (tempo-ral)	R medial temporal lobe (Gad+) (DWI–)	Normal	GAD65 (0.35), VGKC complex (0.25), Lgi1+, Caspr2–, TPO (52.9)	IVIg (reducing frequency over 1.5 y, ongoing)	Seizure freedom (17 mo)
18/M/53	10.5	Changed over time; auras: panic, piloerection multiple per day; "wave-like spells"; CPS: unresponsive staring, amnesia multiple per day; GTC (single)	Cognitive; personality; psychiatric	3/Daily	IED (tempo-ral)\IA (tempo-ral), FS (tem-poral and extra-tempo-ral)	L medial temporal (Gad–) (DWI–), bilateral MTS	Normal	VGKC complex (0.28), Lgi1+, Caspr2–	IVMP (daily, 5; weekly, 9; fortnightly, 4; every 3 wk, 3; monthly, 4; every 3 wk, 4; monthly, 10); MF (22 mo, ongoing)	Seizure improvement (initial seizure freedom, 21 mo, before relapse with new seizure semiology responding to increasing AED); post-ITX VGKC complex, 0.00
19/M/60/	36	Auras: light-headedness, gustatory hallucinosis; CPS: oral automatisms, unresponsive staring	Cognitive; psychiatric	5/Daily	Temporal EA	L medial temporal (Gad–) (DWI–)	Protein level (74)	Ganglionic acetyl-choline receptor (0.08), RF	IVMP (daily, 5; weekly, 5); IVIg (daily, 3; weekly, 6)	No response (subse-quently responded when lacosamide started)
20/F/17	144	Auras: nausea, gustatory hallucinosis, salivation; CPS: unresponsive staring, limb automatisms, unilateral dystonic hand posturing[f]	Cognitive; psychiatric	7/Weekly	IED (tempo-ral), IA (tempo-ral), FS (tempo-ral)		Protein level (53), OCB (9)	GAD65 (197), TPO (871)	Advised but did not return for follow-up	
21/M/62	48	Auras: panic, nausea, tinnitus; CPS: unresponsive staring, limb and oral automatisms	Personality; psychiatric	1/Daily	EA (tempo-ral)	R medial temporal (Gad–) (DWI–)	Normal	None	IVMP (daily, 3; weekly, 6); IVIg (daily, 3; weekly, 6; fortnightly, 6; every 3 wk, 4; monthly, 4)	Seizure freedom (12 mo)
22/F/53	84	CPS: unresponsive staring, oral automatisms	Cognitive; personality	1/Daily	IED (tempo-ral), IA (tempo-ral)	R medial temporal and insula (Gad–) (DWI–), R MTS	Normal	Ma1, Ma2, TPO (60.2)	IVMP (daily, 3; weekly, 6; fortnightly, 3); AZA (3 mo); CMP (monthly, 4 and ongoing for 2 more months)	No response

(Continued)

OTHER NEUROPSYCHIATRIC MANIFESTATIONS

Additional manifestations included memory and cognitive difficulties, 20 (63%); personality changes, 8 (25%); and depression or anxiety, 6 (19%). Neurocognitive changes developed subsequently in 3 of 11 patients who did not have memory or affective changes at presentation (34%).

©2012 American Medical Association. All rights reserved.
Downloaded From: http://archneur.jamanetwork.com/ on 05/25/2013

Table 1. Clinical Characteristics[a] (continued)

Patient/ Sex/ Age, y	Epilepsy Duration, mo	Seizure Type/Semiology	Neurologic Association	No. of AEDs/ Seizure Frequency	EEG Abnormalities (Region)	MRI Probable Inflammatory Changes[b]	CSF Abnormality (Value)[c]	Autoantibody Profile (Titer)[d,e]	ITX (Frequency, No. of Treatments/ Duration)	Post-ITX Seizure Outcome and Antibody Titer
23/M/56	2	Auras and SPS: lightheadedness, depersonalization, L UE jerking and LE flexion; CPS: unresponsive staring; myoclonic seizures[f]		3/Daily	Excessive beta activity		Not done	VGKC complex (3.46), Lgi1+, Caspr2–	IVMP (daily, 3; weekly, 5; fortnightly, 9; every 3 wk, ongoing); MMF (ongoing)	Seizure freedom (6 mo)
24/M/74	0.75	SPS: unilateral facial, UE, and LE twitching; CPS: unresponsive staring, oral and limb automatisms, unilateral dystonic hand posturing	Cognitive	5/Daily	IED (extratemporal), generalized slowing		Protein level (100)	VGKC complex (2.62), Lgi1+, Caspr2–	IVMP (daily, 5; weekly, 6); PLEX (5); AZA (16 mo, ongoing); Pred (tapering)	Seizure freedom (10 mo)
25/F/47	21.5	Auras: epigastric rising, facial flushing, loss of train of thought; CPS: unresponsive staring GTC[f]	Cognitive	9/Daily	IED (temporal), IA (temporal)	Bilateral medial temporal (Gad–) (DWI–), R MTS	OCB (4)	GAD65 (178)	IVMP (daily, 3; weekly, 6); IVIg (daily, 3; weekly, 6)	No response
26/M/56	4.75	Aura: tingling of upper teeth; CPS: confusion; GTC	Cognitive; personality; psychiatric	1/Daily	IED (temporal), IA (temporal and extratemporal)	Bilateral medial temporal (Gad+) (DWI–)	Protein level (68)	VGKC complex (3.21), Lgi1+, Caspr2–	IVMP (daily, 3; weekly, 12; fortnightly, 6; every 3 wk, 4; monthly, 6); PLEX (7); AZA (10 mo and ongoing)	Seizure freedom (4 mo)
27/F/51	4	Auras: flashback memories; CPS: unresponsive staring, aphasia; GTC	Cognitive; personality; psychiatric	3/Daily	IA (temporal)	Bilateral medial temporal (Gad+) (DWI+), bilateral MTS	Protein level (44)	VGKC complex (1.4), Lgi1+, Caspr2–	IVMP (daily, 3; weekly, 8; every 10 d, 3); AZA (stopped owing to allergic reaction); MMF (ongoing)	Seizure freedom (2 mo)
28/F/69	3	Auras (variable): head rush, unilateral visual hallucination, panic; SPS: unilateral facial and UE contraction, oral and limb automatisms; CPS: unresponsive staring	Cognitive; autonomic dysfunction; peripheral nerve excitability	5/Daily	IED (temporal), IA (temporal), generalized slowing	Bilateral medial temporal (Gad–) (DWI–)	Normal	VGKC complex (2.05), Lgi1+, Caspr2–,TPO (142.7)	IVMP (daily, 5); MMF; relapsed 6 mo later during MMF treatment; IVIg (daily, 5; monthly, 4); IVMP (twice weekly, 8; weekly, 12); methotrexate (6 wk, ongoing)	Seizure freedom (2 mo)
29/F/58	18	CPS: unresponsive staring, nonsensical speech	Cognitive	0/Daily	IED (temporal), FS (temporal)		Protein level (54), OCB (7)	GAD65 (404), striational (1:7680), TPO (>950), intrinsic factor antibodies+	IVIg (daily, 3; fortnightly, 4); AZA (26 mo)	No response (no response to IVIg; subsequent response to levetiracetam, after which AZA was started)

(Continued)

NEUROIMAGING FINDINGS

Magnetic resonance imaging brain scans were available for review in all patients (**Figure** and eTable 2). Fifteen (47%) had normal MRIs at the time of initial seizure evaluation. Abnormalities were observed in 22 (17 at initial evaluation, 5 on follow-up imaging): probable inflammatory changes were interpreted in 20 (63%); 2 showed postsurgical changes. Among the 5 patients whose inflammatory changes were only detected on

©2012 American Medical Association. All rights reserved.
Downloaded From: http://archneur.jamanetwork.com/ on 05/25/2013

Table 1. Clinical Characteristics[a] (continued)

Patient/ Sex/ Age, y	Epilepsy Duration, mo	Seizure Type/Semiology	Neurologic Association	No. of AEDs/ Seizure Frequency	EEG Abnormalities (Region)	MRI Probable Inflammatory Changes[b]	CSF Abnormality (Value)[c]	Autoantibody Profile (Titer)[d,e]	ITX (Frequency, No. of Treatments/ Duration)	Post-ITX Seizure Outcome and Antibody Titer
30/M/71	1.5	Auras: chills head to shoulder, piloerection; CPS: euphoria, laughter, nonsensical speech, bilateral UE jerking, confusion; GTC	Cognitive	3/Daily	FS (temporal), generalized slowing	L medial temporal (DWI–)	Protein (66)	VGKC complex (0.62), Lgi1+, Caspr2–	Change of AED led to seizure resolution, but cognitive difficulties persisted; immunotherapy instituted for cognitive changes	
31/M/64	11	Auras/SPS (variable): shivering, surge in head or chest, tunneling of vision, olfactory hallucinosis, word-finding difficulty; CPS: confused behavior, hypersalivation; GTC[f]		3/Daily	IED (temporal), IA (temporal), FS (temporal)		Normal	VGKC complex (0.13), Lgi1–, Caspr2+	IVMP (daily, 5) ×2; IVIg (daily, 5); PLEX (daily, 5); MMF (3 mo); rituximab ×1; IVMP (daily, 3; weekly, ongoing)	Seizure improvement; post-ITX VGKC complex, 0.10
32/F/27	1.5	SPS: aphasia; GTC[f]		5/Daily	IED (temporal and extratemporal), IA (temporal and extratemporal), FS (temporal and extratemporal), generalized slowing	L parietal, occipital, and frontal lobe, L cerebellum	Protein level (49), WBC count (218)	NMDAR	IVMP (daily, 5) ×2; (weekly, 6 and fortnightly, 4 and ongoing); Pred (daily, tapering); rituximab started owing to subsequent clinical, aphasia, and radiological deterioration	Seizure freedom (5 mo)

Abbreviations: AED, antiepileptic drug; ANA, antinuclear antibody; AZA, azathioprine; Caspr2: contactin-associated proteinlike 2; CMP, cyclophosphamide; CPS, complex partial seizures; CRMP-5, collapsin response-mediator protein 5; CSF, cerebrospinal fluid; dexa, dexamethasone; DWI, restricted diffusion; EEG, electroencephalography; ENA, extractable nuclear antigen; EPC, epilepsia partialis continua; FS, focal slowing; Gad, gadolinium enhancing; GAD65, glutamic acid decarboxylase 65; GTC, generalized seizures; IA, ictal activity; IED, interictal epileptiform discharge; ITX, immunotherapy; IVIg, intravenous immune globulin; IVMP, intravenous methylprednisolone; L, left; LE, lower extremity; Lgi1, leucine-rich, glioma inactivated 1; MMF, mycophenolate mofetil; MRI, magnetic resonance imaging; MTS, medial temporal sclerosis; NMDAR, *N*-methyl-D-aspartate receptor; OCB, oligoclonal band; PLEX, plasma exchange; Pred, prednisolone; R, right; RF, rheumatoid factor; SPS, simple partial seizures; TPO, thyroid peroxidase; UE, upper extremity; VGKC, voltage-gated potassium channel; WBC, white blood cell; +, positive; –, negative.

[a] Nonneurologic autoimmune disease or cancer: thyroid disease, patients 1, 7, 8, 10, 15, 25, 27, 28, and 31; celiac sprue: patients 2 and 7; diabetes mellitus, patients 4, 10, 20, 28, and 29; premature menopause, patient 9; psoriasis, patient 17; pernicious anemia, patients 25, 29, and 30; thyroid papillary cancer, patient 2; recurrence of bladder cancer, patient 4; breast cancer, patient 11; prostate cancer, patients 16 and 21; and cervical cancer, patient 27.

[b] Presence and location of MRI inflammatory changes, evidenced by T2/fluid-attenuated inversion recovery hyperintensities.

[c] Unit of measure for cell count is cells per microliter; unit of measure for protein is milligrams per deciliter. Cerebrospinal fluid reference ranges: WBC count, <4/μL; protein, <35 mg/dL; and OCBs, <4.

[d] Autoantibodies reference range for normal values: GAD65 antibody, ≤0.02 nmol/L; neuronal ganglionic acetylcholine receptor antibody, ≤0.02 nmol/L; TPO antibody, <9 IU/mL; VGKC complex antibody, ≤0.02 nmol/L.

[e] For the neural autoantibodies implicated in this study, a recent study[29] showed the following frequencies of these antibodies in 161 normal healthy controls: ganglionic acetylcholine receptor, 0%; CRMP-5, 0%; GAD65, 2.5%; and VGKC complex, <1%.

[f] Video EEG monitoring performed.

[g] Also reported elsewhere.[30]

[h] Also reported elsewhere.[31]

subsequent imaging, the median interval between normal and subsequent abnormal scans was 4 months (range, 1-8 months). Abnormalities deemed inflammatory included swelling and T2 hyperintensity involving the amygdalohippocampal complex (17 patients [53%]) and extramedial temporal structures (6 patients [19%]). Six of 19 gadolinium studies demonstrated contrast enhancement (32%). Five of 19 diffusion-weighted sequence MRIs demonstrated restricted diffusion (26%). Prior to immunotherapy, 4 patients had radiographic features indistinguishable from medial temporal sclerosis.

Whole-body FDG-PET images, performed as a screen for occult malignancies in 20 patients, were reviewed. Brain sections of these studies showed medial temporal region hypermetabolism in 11 patients and left parietal cortex hypermetabolism in 1. No clinical seizures were reported to have occurred during PET acquisition in any patient. However, specific inquiry as to the presence or absence of seizure activity during acquisition is not a part

©2012 American Medical Association. All rights reserved.
Downloaded From: http://archneur.jamanetwork.com/ on 05/25/2013

of the routine procedure during PET, and none were performed with concurrent EEG monitoring. Medial temporal and extratemporal hypometabolism was detected in 1 patient.

AUTOANTIBODY PROFILES AND MALIGNANCY SCREENING

Neural autoantibodies were identified in 29 patients (91%). Specificities were VGKC complex, 18; GAD65, 7; CRMP-5, 2; Ma (PNMA1 and PNMA2), 1; NMDA receptor, 1; and neuronal nicotinic acetylcholine receptor, ganglionic type, 1. Among the 18 patients who had VGKC complex IgG, 14 (78%) bound to Lgi1, 1 bound to Caspr2, and 3 were of unknown specificity (eFigure 1). The 3 patients who lacked detectable neural autoantibodies (patients 7, 11, and 21) had other features that supported the likelihood of autoimmune epilepsy: 2 had inflammatory CSF, all 3 had inflammatory MRI abnormalities, 2 had a personal history of cancer (1 prostate and 1 breast), and 1 had coexistent autoimmune disease (thyroid disease and celiac sprue). None had laboratory findings to indicate an infectious etiology.

The identification of a neural autoantibody led in 3 patients (patients 2, 4, and 16) to prospective detection of cancer: 2 with VGKC complex antibodies had thyroid or prostate carcinoma and 1 patient with CRMP-5 antibody had recurrent bladder cancer. Cerebrospinal fluid abnormalities were found in 19 of 30 patients (63%) evaluated: elevated leukocyte count (>5/μL), 5 patients; CSF-exclusive oligoclonal bands, 5 patients; and elevated protein level (>35 mg/dL), 17 patients.

IMMUNOTHERAPY AND RESPONSE

Immunotherapy was instituted in 27 of 32 patients for the treatment of persistent seizures despite AED therapy (**Table 3**). Initial immunotherapy comprised intravenous methylprednisolone alone (IVMP) (n = 12); intravenous immune globulin alone (IVIg) (n = 3); and combinations of IVMP, IVIg, cyclophosphamide, or plasmapheresis (n = 12). The median follow-up period was 17 months (range, 3-72 months). At last follow-up, 22 of 27 patients (81%) had improved clinically after initiation of immunotherapy. The median time from seizure onset to initiating immunotherapy was 4 months for responders and 22 months for nonresponders ($P < .05$). All 15 VGKC complex antibody–positive patients and 3 of 5 GAD65-seropositive patients (60%) reported benefit ($P < .05$ and $P = .17$, respectively) (eTable 3). Five responders had relapses during follow-up. With further immunotherapy and/or AED treatment, 2 eventually achieved seizure control. Their autoantibody specificities were CRMP-5, 1; GAD65, 1; and VGKC complex (Lgi1), 3. Five patients did not respond to immunotherapy. However, 2 of the 5 demonstrated subsequent improvement after AEDs were changed (patients 19 and 29).

Eighteen patients (67%) achieved seizure freedom over a median period of 10 months (range, 2-48 months). Eight of those patients (44%) were seizure free within 12 weeks of immunotherapy initiation. Eight patients (44%) had no residual deficits, but others experienced residual neurologic deficits, despite achieving seizure freedom. Cognitive and memory concerns were improved but persisted in 8 (44%). Four patients had behavioral or mood changes. One patient (patient 32) had residual aphasia having presented with intractable aphasic seizures and left cortical inflammatory changes. For long-term main-

Table 2. Clinical, CSF, and Autoantibody Profiles[a]

Characteristic	No. (%)
Seizure characteristic	
Age at onset, y, median (SD) [IQR]	56.0 (5-79) [46-63]
Duration of seizures, mo, median (SD) [IQR]	5 (0.75-144) [3-21]
Seizure type	
Simple partial and/or auras	27 (84)
Complex partial	26 (81)
Generalized tonic clonic	17 (53)
Epilepsia partialis continua	3 (9)
Associated clinical features	
Cognitive deficits	20 (63)
Personality	8 (25)
Depression	5 (16)
Anxiety	3 (9)
No. of antiepileptic medications tried prior to immunotherapy	
1	6 (19)
≥2	26 (81)
Seizure frequency at time of immunotherapy trial	
≥1/d	26 (81)
≥1/wk	1 (3)
≥1/mo	5 (16)
Personal history of autoimmune disease(s)	16 (50)
Family history of autoimmune disease(s)	17 (53)
CSF features (n = 30)	
Elevated protein level	17 (57)
Elevated leukocyte count	5 (17)
Oligoclonal band	5 (19)
Normal	11 (38)
Neural autoantibodies	29 (91)
VGKC complex	18 (56)
Median, nmol/L, (range)	0.91 (0.09-4.21)
Lgi1	14/18
Caspr2	1/18
Neither Lgi1 or Caspr2	3/18
GAD65	7 (22)
Median, nmol/L, (range)	178 (0.35-698)
CRMP-5	2 (6)
Ma2	1 (3)
NMDAR	1 (3)
Ganglionic AChR	1 (3)
Median	0.10 nmol/L

Abbreviations: AChR, acetylcholine receptor; Caspr2, contactin-associated proteinlike 2; CRMP-5, collapsin response-mediator protein 5; CSF, cerebrospinal fluid; GAD65, glutamic acid decarboxylase 65; IQR, interquartile range; Lgi1, leucine-rich, glioma-inactivated 1; NMDAR, *N*-methyl-D-aspartate receptor; VGKC, voltage-gated potassium channel.

[a] Reference ranges: GAD65 antibody, 0.00 to 0.02 nmol/L; neuronal ganglionic AChR antibody, 0.00 to 0.02 nmol/L; and VGKC complex antibody, 0.00 to 0.02 nmol/L. Nonneural autoantibodies were detected in 15 patients: thyroid peroxidase, in 12; antinuclear antibody, in 1; extractable nuclear antigen, in 2; rheumatoid factor, in 3; and intrinsic factor, in 2.

©2012 American Medical Association. All rights reserved.
Downloaded From: http://archneur.jamanetwork.com/ on 05/25/2013

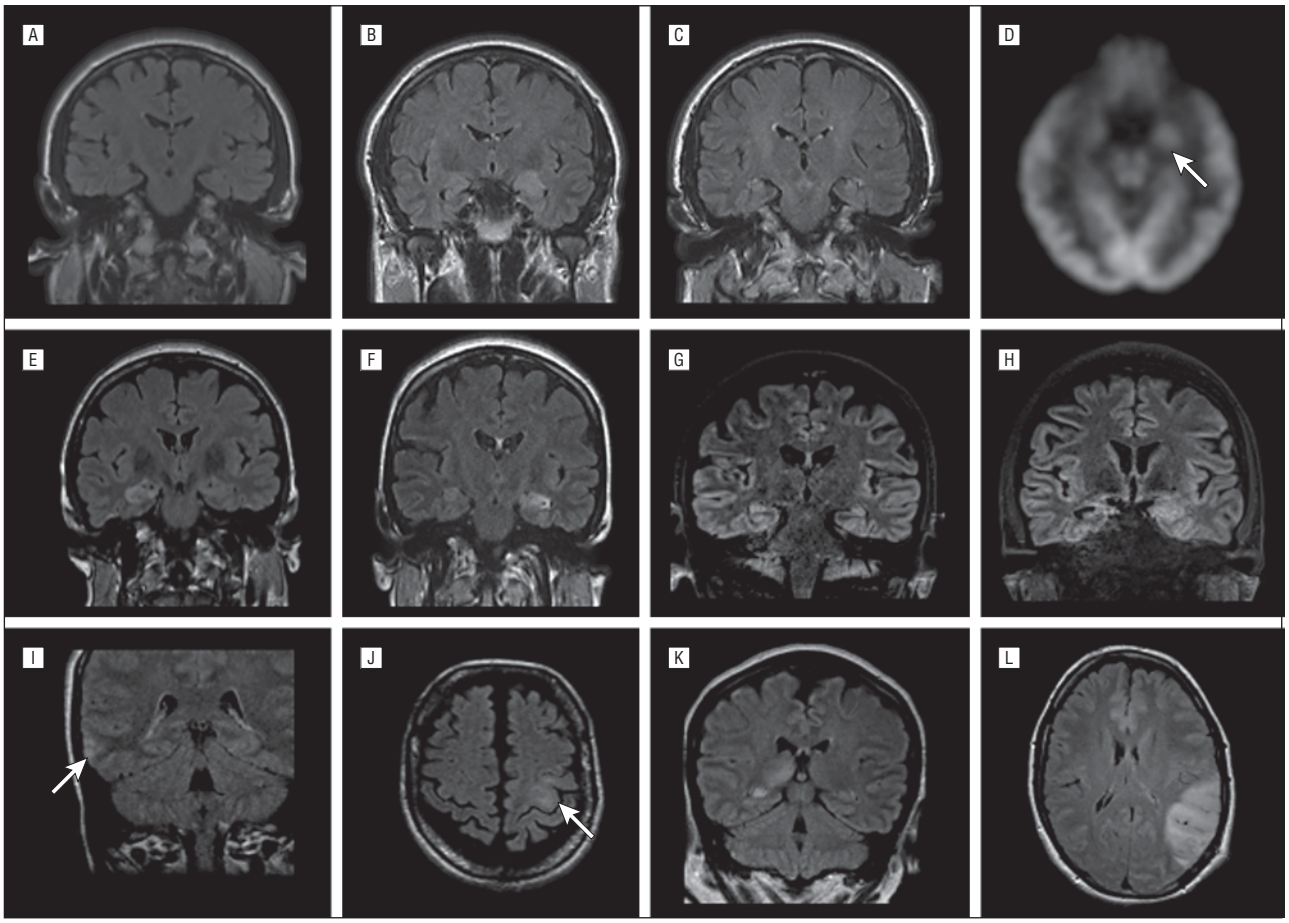

Figure. Representative neuroimaging abnormalities and evolution. Patient 18 presented with a 10-month history of daily episodes of complex partial seizures. Despite normal magnetic resonance imaging (MRI) findings at presentation (A), subsequent preimmunotherapy MRI performed 9 months after seizure onset revealed left amygdala swelling (B) and bilateral hippocampal hyperintensity and atrophy (C). Radiolabeled fluorodeoxyglucose positron emission tomography brain scan showed hypermetabolism within the left amygdala (D) (arrow). Patient 27 had a 4-month history of daily complex partial seizures. Brain MRI revealed T2 hyperintensity within the right amygdalohippocampal region 3 months following seizure onset (E), which evolved to include the contralateral region 2 months later (F). Repeated MRI 3 months later before immunotherapy initiation demonstrated radiographic evidence of bilateral mesial temporal sclerosis (G) and residual left amygdala swelling and hyperintensity (H). Patient 3 presented with partial and secondary generalized seizures. There was signal abnormality in the right lateral temporal lobe (I) (arrow) after her first generalized tonic-clonic seizure, which occurred several weeks after the onset of partial seizures. Patient 11 was diagnosed with epilepsia partialis continua and had abnormal signal in the left precentral gyrus (arrow) 2 months after seizure onset (J). Patient 7 developed status epilepticus after a 3-month history of complex partial seizures. Admission MRI revealed right thalamic and medial temporal hyperintensities (K). Patient 32 presented with generalized tonic-clonic seizure and subsequently developed antiepileptic drug–intractable aphasic seizures. Presentation MRI demonstrated pronounced signal abnormality in the left frontoparietal region (L).

tenance, immunotherapy comprised azathioprine only, 2; mycophenolate mofetil only, 11; or combinations of azathioprine, mycophenolate mofetil, prednisolone, rituximab, or methotrexate, 5.

Postimmunotherapy imaging was available for review in 15 of the patients whose scans had revealed evidence of inflammation (eTable 2). Four patients had no evidence of radiological changes. Five showed reduction in hyperintensity size, and 5 patients developed hippocampal atrophy and sclerosis. One patient with initial T2 hyperintensity in the right posterolateral temporal lobe before immunotherapy had complete resolution of this abnormality. Postimmunotherapy antibody values were available for 10 patients (Table 1, last column) who had a favorable immunotherapy response. Of 7 VGKC complex–seropositive patients, posttherapy values were lower in 3 and undetectable in another 3. CRMP-5 IgG did not persist in 2 patients and GAD65 antibody level decreased in 1.

One patient (patient 30) who had VGKC complex antibodies was seizure free for a 2-week period after receiving a third AED. An immunotherapy trial was initiated because of significant residual memory impairment but not for seizures; cognition improved within 3 months, and seizures did not recur. Four patients did not receive immunotherapy. Two patients declined, and the need for immunotherapy in the third patient (patient 2) was obviated because he became seizure free following removal of a thyroid papillary carcinoma found in the malignancy screening that was prompted by VGKC complex antibody detection. Seizure resolution followed. A fourth patient (patient 6), whose seizures also were associated with VGKC complex antibodies (3.5 nmol/L; normal range, ≤0.02 nmol/L), was refractory to the first AED (levetiracetam), but seizures were controlled after a second AED was started (lamotrigine). The AED therapy was discontinued after 3 years, and the patient remained seizure free 12 months later.

©2012 American Medical Association. All rights reserved.
Downloaded From: http://archneur.jamanetwork.com/ on 05/25/2013

All 32 patients for whom we describe clinical, serologic, and imaging findings had refractory epilepsy of presumed autoimmune basis. The intractability, high seizure frequency, and striking improvement in seizure control achieved following immunotherapy in many warrant emphasis: 81% had significant improvement in seizure status and 67% achieved seizure freedom, a majority of whom were AED resistant.

Our study supports previously noted links between neurologic autoimmunity and epilepsy.[18-21,26-28] Recurrent seizures were the early and predominant clinical manifestation in the patients of our report. An autoimmune etiology is identified most readily in patients who present with the full syndrome of limbic encephalitis, characterized by subacute memory impairment with affective changes and temporal lobe seizures. The diagnosis of autoimmune limbic encephalitis is aided by detection of neural autoantibodies with radiological or pathological evidence of temporomedial inflammation and in some cases a history of neoplasia in the preceding 5 years.[32] Limbic encephalitis has been suggested as a precedent of hippocampal sclerosis and adult-onset temporal lobe epilepsy.[6,33] In our report, one-third of the patients had seizures as their exclusive presentation without other recognized clinical accompaniments of limbic encephalitis. Although the remaining two-thirds had additional neurologic problems, including cognitive and personality changes, they had presented with predominant concerns of high daily seizure burden. This prevented clear distinction of the contribution of inflammatory limbic lesions vs seizure activity to the evolving neurocognitive impairment. Furthermore, 15 patients had normal MRI brain scans at initial presentation, and among 12 patients who had subsequent MRIs, a median of 4 months elapsed before subsequent imaging showed development of inflammatory changes in 5.

The primary aim of this study was to report the clinical features and immunotherapy response in a cohort diagnosed with autoimmune epilepsy. The study was not designed to compare clinical features of this entity with those of epilepsy from other etiologies. The diagnosis of autoimmune epilepsy requires a high level of suspicion at initial evaluation. The clinical presentations in our patients were heterogeneous, but some general observations can be made. Data from the current cohort suggest that autoimmune investigation should be considered in the presence of 1 or more of the following: an unusually high seizure frequency, intraindividual seizure variability or multifocality, AED resistance, personal or family history of autoimmunity (either organ specific [eg, thyroid disease, diabetes mellitus, pernicious anemia, or celiac disease] or non–organ specific [rheumatoid arthritis or systemic lupus erythematosus]), or recent or past neoplasia. Serological testing is increasingly valuable as an aid to establishing the diagnosis of an autoimmune etiology. As illustrated in the patients we presented, other laboratory and radiological findings may be normal. Serial MRI findings were consistent with inflammation in several patients. When detected, these radiological findings (sometimes indistinguishable from medial temporal sclerosis) supported the diagnosis of autoimmune epilepsy. However, MRIs were normal in about half of patients. Cerebrospinal fluid was also normal in nearly half the patients despite the presence of an autoimmune neurologic disorder. Hence, the presence of normal CSF or MRI does not exclude an immune-mediated process. The role of brain FDG-PET in these patients warrants further study. While focal hypometabolism is more typically seen in the epilepsy population, focal hypermetabolism was fortuitously noted in this cohort who underwent whole-body FDG-PET primarily for malignancy purposes. It is our continuing observation that autoimmune epilepsies are underrecognized.

Table 3. Epilepsy Outcome

Outcome	No./Total No. (%)
Immunotherapy for epilepsy (n = 27)	
Duration of follow-up, mo, median (range) [IQR]	17 (3-72) [10-31]
Seizure freedom	18 (67)
Duration of seizure freedom, mo, median (range) [IQR]	10 (2-48) [4-17]
Seizure freedom ≤3 mo after immunotherapy	8/18 (44)
Seizure freedom >3 mo after immunotherapy	10/18 (56)
Seizure improvement	4 (15)
No change	5 (18)
No immunotherapy for epilepsy (n = 5)	
Resolved after cancer detected and treated	1
Resolved during AED treatment[a]	2
Recommended but declined	2

Abbreviations: AED, antiepileptic drug; IQR, interquartile range.
[a] Patient who presented with daily seizures managed to achieve seizure freedom of approximately 2 weeks after trial of third AED. At this point, immunotherapy was instituted because of residual cognitive difficulties in the setting of voltage-gated potassium channel complex autoantibody.

A majority of the patients in this study had neuronal VGKC complex autoantibodies. This serological marker aids the diagnosis of idiopathic and less commonly paraneoplastic autoimmune neurologic disorders. It is impressive that the seizure disorder was immunotherapy responsive in all seropositive patients. Voltage-gated potassium channel complex autoimmunity was first reported in patients with neuromyotonia[34] (Isaacs syndrome), Morvan syndrome,[35] and limbic encephalitis.[36] A broader spectrum of neurologic phenotypes affecting all levels of the nervous system has been described.[30,37] Two independent groups recently reported that the target autoantigens in these disorders are generally not VGKC complex channel proteins per se but neuronal proteins (Lgi1 and Caspr2) that respectively associate with a subset of Kv1 VGKC complexes at synapses and at juxtaparanodes of myelinated axons.[8,9] Lgi1 was the target antigen in 78% of our VGKC complex antibody–positive patients. One had antibodies targeting Caspr2. Previous reports have implicated Lgi1 as the principal target antigen in limbic encephalitis, while Caspr2 is more commonly, but not exclusively, associated with peripheral nervous system manifestations.[8,9] Lgi1 is recognized as a causative gene in autosomal-dominant partial epi-

©2012 American Medical Association. All rights reserved.
Downloaded From: http://archneur.jamanetwork.com/ on 05/25/2013

lepsy with auditory features.[38] It encodes a secreted protein that links 2 epilepsy-related receptors, ADAM22 and ADAM23, creating a complex that incorporates presynaptic potassium channels and postsynaptic AMPA receptor scaffolds. Fukata and colleagues[39] demonstrated that disruption of the Lgi1-linked synaptic complex causes abnormal synaptic transmission and epilepsy. Recently, faciobrachial dystonic seizures were reported to precede Lgi1 antibody–associated encephalitis, suggesting that early immunotherapy could prevent the evolution to limbic encephalitis.[22] We identified similar seizures in 6 of 14 (43%) Lgi1-seropositive patients in this cohort, often accompanied by other seizure semiologies. We also noted piloerection as a semiological feature in 4 of 14 (29%).

One patient in our study had NMDA receptor autoantibodies.[23] *N*-methyl-D-aspartate receptor autoimmune encephalitis is often accompanied by ovarian teratoma and a stereotypic clinical evolution starting with a viral-like prodrome, psychiatric symptoms, memory impairment, dyskinesias, seizures, and progressing coma and hypoventilation.[40] Most reported cases have had seizures at presentation,[41] but these were overshadowed or accompanied by neurocognitive disturbances. Our patient presented with AED-intractable aphasic seizures and evolving left cortical inflammatory changes.

When autoimmune epilepsy is suspected on clinical grounds, CSF evaluation and comprehensive screening for neural autoantibodies are indicated. Selective autoantibody testing is not advised because no single neural antibody is definitively associated with seizures. Failure to detect a neural antibody does not exclude the diagnosis of autoimmune epilepsy when other clinical clues exist. If autoimmune epilepsy is suspected, a trial of 6 to 12 weeks of immunotherapy (IVMP or IVIg daily for 3 days and then weekly) is justifiable in the absence of other treatment options and may serve as additional evidence for an autoimmune etiology when a favorable seizure response is observed.[42] In 22 of 27 patients (81%), this therapeutic trial was positive, and early treatment was associated with a favorable outcome ($P < .05$). Long-term immunosuppressive treatment, overlapping with gradual taper of IVMP or IVIg, should be considered for patients whose seizures respond favorably to the initial trial of immunotherapy. Despite this, relapses may still occur.

Our study is limited by its retrospective design and the fact that AED changes were not restricted during the period of immunotherapy. The patients' poorly controlled seizures necessitated continuing AED changes during immunotherapy initiation, complicating interpretation of the contribution of immunotherapy to seizure control. However, the likelihood that such changes accounted for improved clinical response in these patients is well below the proportion of patients responding to immunotherapy trial.[1] Clinical experience suggests that immunotherapy should not be used alone to control seizures but should be used in combination with AEDs to optimize seizure control. The clinical spectrum of autoimmune epilepsy is still unknown. In a series of patients with epilepsy, VGKC complex antibodies were detected in 10%; NMDA receptor antibodies, in 7% of newly diagnosed patients; and GAD65 antibodies, in 1.6% to 1.7%.[43] It is conceivable that we are only identifying patients with the most severe presentations in this heterogeneous group, and the burden of this entity remains underappreciated in patients with milder epilepsies. Questions remaining unanswered include the natural history of autoimmune epilepsy, the selection criteria for patients with epilepsy most likely to benefit from an autoimmune evaluation, the timing for immunotherapy trial, and optimal duration of long-term immunotherapy maintenance.

Accepted for Publication: October 28, 2011.
Published Online: March 26, 2012. doi:10.1001/archneurol.2011.2983
Correspondence: Sean J. Pittock, MD, Mayo Clinic, Department of Neurology, 200 First St SW, Rochester, MN 55905 (pittock.sean@mayo.edu).
Author Contributions: *Study concept and design:* Quek, Britton, So, Lennon, Shin, Cascino, and Pittock. *Acquisition of data:* Quek, Britton, McKeon, Shin, Klein, Watson, Lagerlund, Cascino, Worrell, Wirrell, Nickels, Aksamit, and Pittock. *Analysis and interpretation of data:* Quek, Britton, McKeon, So, Shin, Watson, Kotsenas, Cascino, Wirrell, Noe, and Pittock. *Drafting of the manuscript:* Quek, Britton, Shin, Cascino, Worrell, and Pittock. *Critical revision of the manuscript for important intellectual content:* Quek, Britton, McKeon, So, Lennon, Shin, Klein, Watson, Kotsenas, Lagerlund, Cascino, Worrell, Wirrell, Nickels, Aksamit, Noe, and Pittock. *Statistical analysis:* Quek and Cascino. *Obtained funding:* Lennon and Pittock. *Administrative, technical, and material support:* Britton, Cascino, Worrell, and Nickels. *Study supervision:* Britton, So, Shin, Klein, Cascino, Wirrell, Aksamit, and Pittock.
Financial Disclosure: Dr McKeon receives research support from the Guthy-Jackson Charitable Foundation. Dr Cascino serves as associate editor of *Neurology* and receives honoraria from the American Academy of Neurology. He receives research support from NeuroPace, Inc and National Institutes of Health grant RO1 NS053998. Dr Wirrell serves on the editorial boards of *Epilepsia, Journal of Child Neurology*, and the *Canadian Journal of Neurological Sciences* and receives research support from the Mayo Foundation. Dr Noe receives research support from NeuroPace, Inc. Dr Lennon is a named inventor on a patent (7101679 issued 2006) relating to aquaporin-4 antibodies for the diagnosis of neuromyelitis optica (NMO) and receives royalties for this technology; is a named inventor on patents (12/678 350 filed 2010 and 12/573 942 filed 2008) that relate to functional aquaporin-4/NMO-IgG assays and NMO-IgG as a cancer marker; and receives research support from the Guthy-Jackson Charitable Foundation. Dr Pittock is a named inventor on patents (12/678 350 filed 2010 and 12/573 942 filed 2008) that relate to functional aquaporin-4/NMO-IgG assays and NMO-IgG as a cancer marker and receives research support from Alexion Pharmaceuticals, Inc, the Guthy-Jackson Charitable Foundation, and the National Institutes of Health. EUROIMMUN provided assay kits for identifying VGKC complex IgGs of Lgi1 and Caspr2 specificities.
Online-Only Material: The eTables and eFigure are available at http://www.archneurol.com. Visit http://www

©2012 American Medical Association. All rights reserved.
Downloaded From: http://archneur.jamanetwork.com/ on 05/25/2013

.archneurol.com to listen to an author interview about this article.

Additional Contributions: We thank Jade Martin, BS, Amy Moses, BA, Vickie Mewhorter, and Debby Cheung, BS, for technical assistance, Evelyn Posthumus and Connie Brekke for manuscript assistance, and EUROIMMUN for generously providing assay kits for identifying VGKC complex IgGs of Lgi1 and Caspr2 specificities.

REFERENCES

1. Kwan P, Brodie MJ. Early identification of refractory epilepsy. *N Engl J Med*. 2000; 342(5):314-319.
2. Berg AT, Berkovic SF, Brodie MJ, et al. Revised terminology and concepts for organization of seizures and epilepsies: report of the ILAE Commission on Classification and Terminology, 2005-2009. *Epilepsia*. 2010;51(4):676-685.
3. Pittock SJ, Lucchinetti CF, Parisi JE, et al. Amphiphysin autoimmunity: paraneoplastic accompaniments. *Ann Neurol*. 2005;58(1):96-107.
4. Dalmau J, Rosenfeld MR. Paraneoplastic syndromes of the CNS. *Lancet Neurol*. 2008;7(4):327-340.
5. Hoffmann LA, Jarius S, Pellkofer HL, et al. Anti-Ma and anti-Ta associated paraneoplastic neurological syndromes: 22 newly diagnosed patients and review of previous cases. *J Neurol Neurosurg Psychiatry*. 2008;79(7):767-773.
6. Bien CG, Urbach H, Schramm J, et al. Limbic encephalitis as a precipitating event in adult-onset temporal lobe epilepsy. *Neurology*. 2007;69(12):1236-1244.
7. Vincent A, Buckley C, Schott JM, et al. Potassium channel antibody-associated encephalopathy: a potentially immunotherapy-responsive form of limbic encephalitis. *Brain*. 2004;127(pt 3):701-712.
8. Lai M, Huijbers MG, Lancaster E, et al. Investigation of LGI1 as the antigen in limbic encephalitis previously attributed to potassium channels: a case series. *Lancet Neurol*. 2010;9(8):776-785.
9. Irani SR, Alexander S, Waters P, et al. Antibodies to Kv1 potassium channel-complex proteins leucine-rich, glioma inactivated 1 protein and contactin-associated protein-2 in limbic encephalitis, Morvan's syndrome and acquired neuromyotonia. *Brain*. 2010;133(9):2734-2748.
10. Graus F, Keime-Guibert F, Reñe R, et al. Anti-Hu-associated paraneoplastic encephalomyelitis: analysis of 200 patients. *Brain*. 2001;124(pt 6):1138-1148.
11. Marnane M, Vincent A, Hutchinson M. New-onset focal epilepsy with palatal tremor and glutamic acid decarboxylase antibodies responding to intravenous immunoglobulin. *J Neurol*. 2008;255(10):1603-1604.
12. Malter MP, Helmstaedter C, Urbach H, Vincent A, Bien CG. Antibodies to glutamic acid decarboxylase define a form of limbic encephalitis. *Ann Neurol*. 2010; 67(4):470-478.
13. Thieben MJ, Lennon VA, Boeve BF, Aksamit AJ, Keegan M, Vernino S. Potentially reversible autoimmune limbic encephalitis with neuronal potassium channel antibody. *Neurology*. 2004;62(7):1177-1182.
14. Yu Z, Kryzer TJ, Griesmann GE, Kim K, Benarroch EE, Lennon VA. CRMP-5 neuronal autoantibody: marker of lung cancer and thymoma-related autoimmunity. *Ann Neurol*. 2001;49(2):146-154.
15. Pittock SJ, Yoshikawa H, Ahlskog JE, et al. Glutamic acid decarboxylase autoimmunity with brainstem, extrapyramidal, and spinal cord dysfunction. *Mayo Clin Proc*. 2006;81(9):1207-1214.
16. Saiz A, Blanco Y, Sabater L, et al. Spectrum of neurological syndromes associated with glutamic acid decarboxylase antibodies: diagnostic clues for this association. *Brain*. 2008;131(pt 10):2553-2563.
17. Barajas RF, Collins DE, Cha S, Geschwind MD. Adult-onset drug-refractory seizure disorder associated with anti-voltage-gated potassium-channel antibody. *Epilepsia*. 2010;51(3):473-477.
18. Majoie HJ, de Baets M, Renier W, Lang B, Vincent A. Antibodies to voltage-gated potassium and calcium channels in epilepsy. *Epilepsy Res*. 2006;71(2-3): 135-141.
19. Irani SR, Buckley C, Vincent A, et al. Immunotherapy-responsive seizure-like episodes with potassium channel antibodies. *Neurology*. 2008;71(20):1647-1648.
20. Liimatainen S, Peltola M, Sabater L, et al. Clinical significance of glutamic acid decarboxylase antibodies in patients with epilepsy. *Epilepsia*. 2010;51(5):760-767.
21. Peltola J, Kulmala P, Isojärvi J, et al. Autoantibodies to glutamic acid decarboxylase in patients with therapy-resistant epilepsy. *Neurology*. 2000;55(1):46-50.
22. Irani SR, Michell AW, Lang B, et al. Faciobrachial dystonic seizures precede Lgi1 antibody limbic encephalitis. *Ann Neurol*. 2011;69(5):892-900.
23. Dalmau J, Gleichman AJ, Hughes EG, et al. Anti-NMDA-receptor encephalitis: case series and analysis of the effects of antibodies. *Lancet Neurol*. 2008;7 (12):1091-1098.
24. Lancaster E, Lai M, Peng X, et al. Antibodies to the GABA(B) receptor in limbic encephalitis with seizures: case series and characterisation of the antigen. *Lancet Neurol*. 2010;9(1):67-76.
25. Lai M, Hughes EG, Peng X, et al. AMPA receptor antibodies in limbic encephalitis alter synaptic receptor location. *Ann Neurol*. 2009;65(4):424-434.
26. Vincent A, Irani SR, Lang B. The growing recognition of immunotherapy-responsive seizure disorders with autoantibodies to specific neuronal proteins. *Curr Opin Neurol*. 2010;23(2):144-150.
27. McKnight K, Jiang Y, Hart Y, et al. Serum antibodies in epilepsy and seizure-associated disorders. *Neurology*. 2005;65(11):1730-1736.
28. Irani SR, Bien CG, Lang B. Autoimmune epilepsies. *Curr Opin Neurol*. 2011;24(2): 146-153.
29. Kraichely RE, Farrugia G, Pittock SJ, Castell DO, Lennon VA. Neural autoantibody profile of primary achalasia. *Dig Dis Sci*. 2010;55(2):307-311.
30. Tan KM, Lennon VA, Klein CJ, Boeve BF, Pittock SJ. Clinical spectrum of voltage-gated potassium channel autoimmunity. *Neurology*. 2008;70(20):1883-1890.
31. Flanagan EP, McKeon A, Lennon VA, et al. Autoimmune dementia: clinical course and predictors of immunotherapy response. *Mayo Clin Proc*. 2010;85(10): 881-897.
32. Bien CG, Elger CE. Limbic encephalitis: a cause of temporal lobe epilepsy with onset in adult life. *Epilepsy Behav*. 2007;10(4):529-538.
33. Bien CG, Schulze-Bonhage A, Deckert M, et al. Limbic encephalitis not associated with neoplasm as a cause of temporal lobe epilepsy. *Neurology*. 2000; 55(12):1823-1828.
34. Hart IK, Waters C, Vincent A, et al. Autoantibodies detected to expressed K+ channels are implicated in neuromyotonia. *Ann Neurol*. 1997;41(2):238-246.
35. Barber PA, Anderson NE, Vincent A. Morvan's syndrome associated with voltage-gated K+ channel antibodies. *Neurology*. 2000;54(3):771-772.
36. Buckley C, Oger J, Clover L, et al. Potassium channel antibodies in two patients with reversible limbic encephalitis. *Ann Neurol*. 2001;50(1):73-78.
37. McKeon A, Marnane M, O'connell M, Stack JP, Kelly PJ, Lynch T. Potassium channel antibody associated encephalopathy presenting with a frontotemporal dementia like syndrome. *Arch Neurol*. 2007;64(10):1528-1530.
38. Kalachikov S, Evgrafov O, Ross B, et al. Mutations in LGI1 cause autosomal-dominant partial epilepsy with auditory features. *Nat Genet*. 2002;30(3):335-341.
39. Fukata Y, Lovero KL, Iwanaga T, et al. Disruption of LGI1-linked synaptic complex causes abnormal synaptic transmission and epilepsy. *Proc Natl Acad Sci U S A*. 2010; 107(8):3799-3804.
40. Dalmau J, Lancaster E, Martinez-Hernandez E, Rosenfeld MR, Balice-Gordon R. Clinical experience and laboratory investigations in patients with anti-NMDAR encephalitis. *Lancet Neurol*. 2011;10(1):63-74.
41. Niehusmann P, Dalmau J, Rudlowski C, et al. Diagnostic value of N-methyl-D-aspartate receptor antibodies in women with new-onset epilepsy. *Arch Neurol*. 2009;66(4):458-464.
42. McKeon A, Lennon VA, Pittock SJ. Immunotherapy-responsive dementias and encephalopathies. *Continuum*. 2010;16(2):80-101.
43. Bien CG, Scheffer IE. Autoantibodies and epilepsy. *Epilepsia*. 2011;52(suppl 3): 18-22.

©2012 American Medical Association. All rights reserved.
Downloaded From: http://archneur.jamanetwork.com/ on 05/25/2013